

PROSPECTIVE THREE-DIMENSIONAL ANALYSIS OF STRUCTURE AND FUNCTION IN VITREOMACULAR ADHESION CURED BY PHARMACOLOGIC VITREOLYSIS

Kevin R. Tozer, BS,*† Wolfgang Fink, PhD,†‡§¶** Alfredo A. Sadun, MD, PhD, FARVO,† Jerry Sebag, MD, FACS, FRCOphth, FARVO*†

Purpose: To prospectively characterize macular structure and function as assessed by combined three-dimensional spectral-domain optical coherence tomography and scanning laser ophthalmoscopy and 3D computer-automated threshold Amsler grid, respectively, in a patient undergoing pharmacologic vitreolysis for vitreomacular adhesion with tractional cysts.

Methods: Combined 3D optical coherence tomography and scanning laser ophthalmoscopy measured macular volume and 3D computer-automated threshold Amsler grid quantified central visual field function by determining the absolute percent magnitude lost (cumulative value of total visual field loss over all tested levels) before and for a period of 6 months after pharmacologic vitreolysis for vitreomacular adhesion with a single intravitreal injection of microplasmin (125 μg ; ThromboGenics).

Results: Ocriplasmin pharmacologic vitreolysis released vitreomacular adhesion by 2 weeks and decreased macular volume from 0.32 μL to 0.15 μL by 1 year after injection. There was a concomitant 4-fold improvement in visual function as measured by 3D computer-automated threshold Amsler grid (percent of central visual field lost) and Snellen visual acuity improved from 20/200 to 20/40.

Conclusion: For assessing macular function improvement in conjunction with structural reintegration after pharmacologic vitreolysis for vitreomacular adhesion, 3D computer-automated threshold Amsler grid is a useful tool. Both 3D measurements quantitatively characterized the resolution of this patient's vitreomacular adhesion, suggesting that this is a useful approach to quantifying macular structure and function as indices of the severity of disease and the response to therapy.

RETINAL CASES & BRIEF REPORTS 7:57–61, 2013

*From the *VMR Institute, Huntington Beach, California; †Doheny Eye Institute, Keck School of Medicine, University of Southern California, Los Angeles, California; ‡ECE Department, §BME Department, and ¶Department of Ophthalmology and Vision Science, The University of Arizona, Tucson, Arizona; and **Division of Physics, Mathematics and Astronomy, California Institute of Technology, Pasadena, California.*

Recent advances in ophthalmic diagnostic technology have improved the way vitreoretinal diseases are diagnosed and monitored, but there are still

limitations in the ability to assess function. Three-dimensional computerized threshold Amsler grid (3D-CTAG) was developed by Fink and Sadun¹ to quantitate macular function. This test combines the traditional Amsler grid with contrast sensitivity testing via the use of a touch-sensitive computer screen. While sitting 30 cm from the center of the screen and focusing on a central fixation marker with a single eye, a patient uses their index finger to outline areas of metamorphopsia or scotomata at several predetermined contrast levels. The software combines the outlined areas and, using topographical contour rings, creates a 3D plot of

the patient's visual field abnormality with the z-axis indicating the different contrast sensitivity levels and the x-y plane representing the central visual field. Using this approach, 3D-CTAG has previously been shown to correlate well with automated perimetry while being both faster (4–5 minutes per eye) and yielding a higher spatial resolution of 1° (Nazemi et al² and Kim et al³). Unlike simple visual acuity, which tests only the central 4° of vision, 3D-CTAG measures a 25° field. This test has been used to characterize numerous diseases, such as age-related macular degeneration (Nazemi et al⁴ and Robison et al⁵), diabetic macular edema (Jivrajka et al⁶), glaucoma suspects (Nazemi et al²), and various optic neuropathies (Kim et al³). Three-dimensional CTAG has the added benefit of providing quantitative indices that can be used to follow changes in visual function over time. One valuable 3D-CTAG index is the *absolute percent magnitude lost*, which incorporates all five tested contrast levels to calculate the cumulative percent of visual field lost. This index is calculated by dividing the number of points tested where a defect was detected by the total number of points tested and describes the absolute size of the defect regardless of its shape. Using this index provides an objective and reproducible way to measure temporal changes in disease severity on a functional level and quantify the response to therapy.

Similarly, spectral-domain optical coherence tomography (OCT) combined with scanning laser ophthalmoscopy (SD-OCT/SLO) provides 3-D quantitative indices that can be followed prospectively, such as macular volume and thickness. Combining the superior resolution of SD-OCT with a confocal SLO allows for precise correlation of a quantitative measurement to a specific fundus location, thus making it more reliable to track changes in macular structure over time.

Vitreomacular adhesion (VMA) is presently treated surgically with pars planar vitrectomy and membrane peeling, often with chromodissection (Bababeygy and Sebag⁷). Although effective, this surgical approach is not without inherent risks and costs. Recent developments in pharmacologic vitreolysis may obviate the need for surgery in the future (Sebag^{8,9}). Initially, pharmacologic agents were tested as adjuncts to surgery, but recent work has explored the potential

of pharmacologic vitreolysis as a stand-alone treatment for inducing a total posterior vitreous detachment without surgery. One agent that is currently under development is ocriplasmin, a 29-kDa recombinant truncated form of human plasmin (Stalmans et al¹⁰).

In this report, we characterize the 3D structural and functional changes in a patient with VMA and cystic changes who successfully underwent pharmacologic vitreolysis with a single injection of ocriplasmin. The patient was followed prospectively for 15 months starting before treatment, with both 3D-CTAG and 3D SD-OCT/SLO.

Case Report

A 61-year-old white woman presented with the chief complaint of vision loss and distortions in the right eye of 3-month duration. Best-corrected Early Treatment Diabetic Retinopathy Study visual acuity was 20/200 in the right eye and 20/20-3 in the left eye. Combined OCT/SLO (OPTOS, Southborough, MA) revealed an anomalous posterior vitreous detachment with vitreous adhesion to the macula and optic nerve head (Figure 1). Tractional cysts were present with a central macular volume (central 1 mm Early Treatment Diabetic Retinopathy Study region) measuring 0.32 μL (normal = 0.16 μL [El-Ashry et al¹¹]). The linear distance of VMA was 515 μm in the horizontal and 525 μm in the vertical axes. Three-dimensional CTAG (proprietary software on IBM Pentium II PC running Windows 98) testing revealed a central conical defect (Figure 2 top) with 2.24 absolute percent magnitude

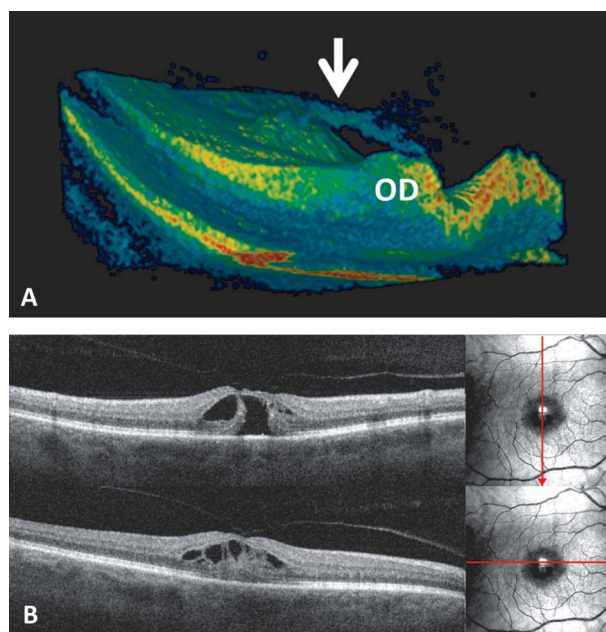


Fig. 1. Combined SD-OCT/SLO of VMA (before treatment). **A.** Combined 3D SD-OCT/SLO imaging before treatment demonstrating vitreous attachment to both the macula and optic disk (OD). The macula is elevated by traction caused by the vitreous membrane (arrow). **B.** Transverse two-dimensional OCT/SLO imaging demonstrating VMA and prominent cystoid spaces in the underlying central macula.

Supported by VMR Consulting, Inc, and Research to Prevent Blindness.

W. Fink and A. A. Sadun have patented proprietary interest in the 3D computer-automated threshold Amsler grid test described in this study. J. Sebag is a consultant and minor shareholder of ThromboGenics.

Reprint requests: Kevin R. Tozer, BS, 1355 San Pablo Street, DVRC 307, Los Angeles, CA 90033; e-mail: ktozer@usc.edu

lost. The patient was enrolled in the MIVI-IIT (Microp lasmin for IntraVitreous Injection for treatment vitreomacular Traction) clinical trial and, following informed consent, was randomized to a single injection (125 μg in 100 μL) of microplasmin (Ocriplasmin; Thrombogenics, Leuven, Belgium). Table 1 shows the progression of all quantitative structural (3D-OCT/SLO) and functional (visual acuity and 3D-CTAG) indices over time.

One week after injection, the patient had decreased metamorphopsia and best-corrected visual acuity of 20/40-2 in the treated eye. At 2 weeks after the injection, 3D-OCT/SLO imaging revealed resolution of VMA and vitreopapillary adhesion (Figure 3). Macular volume had decreased to 0.22 μL (31.25% improvement from preinjection level), and nearly all cystoid spaces had resolved. Repeat 3D-CTAG evaluation revealed a smaller central conical defect (Figure 2) with a 0.66 absolute percent magnitude lost (nearly 4-fold improvement from preinjection level). At 1 month, the macular volume had only changed slightly to 0.21 μL while the absolute percent magnitude lost on 3D-CTAG actually increased slightly to 0.99. At 6 months after injection, the macular volume was still 0.21 mL, and 3D-CTAG measured an absolute percent magnitude lost of 0.65. At 15 months, macular volume improved to 0.15 μL .

Discussion

The past two decades have witnessed considerable improvement in technology to image macular structure; however, there has been little concurrent progress in assessing macular function. This case demonstrates the utility of 3D-CTAG in assessing macular dysfunction and its recovery after successful resolution of VMA with ocriplasmin pharmacologic vitreolysis. The functional assessment by 3D-CTAG mirrored the structural improvement, as demonstrated by combined 3D SD-OCT/SLO. Although visual acuity registered a similar improvement, this indexed only foveal function (4° central visual field), while 3D-CTAG quantified the central 25° macular function improvement. Both the 3D-CTAG and the volumetric measurements of combined SD-OCT/SLO showed that while major improvement occurred in the first 2 weeks

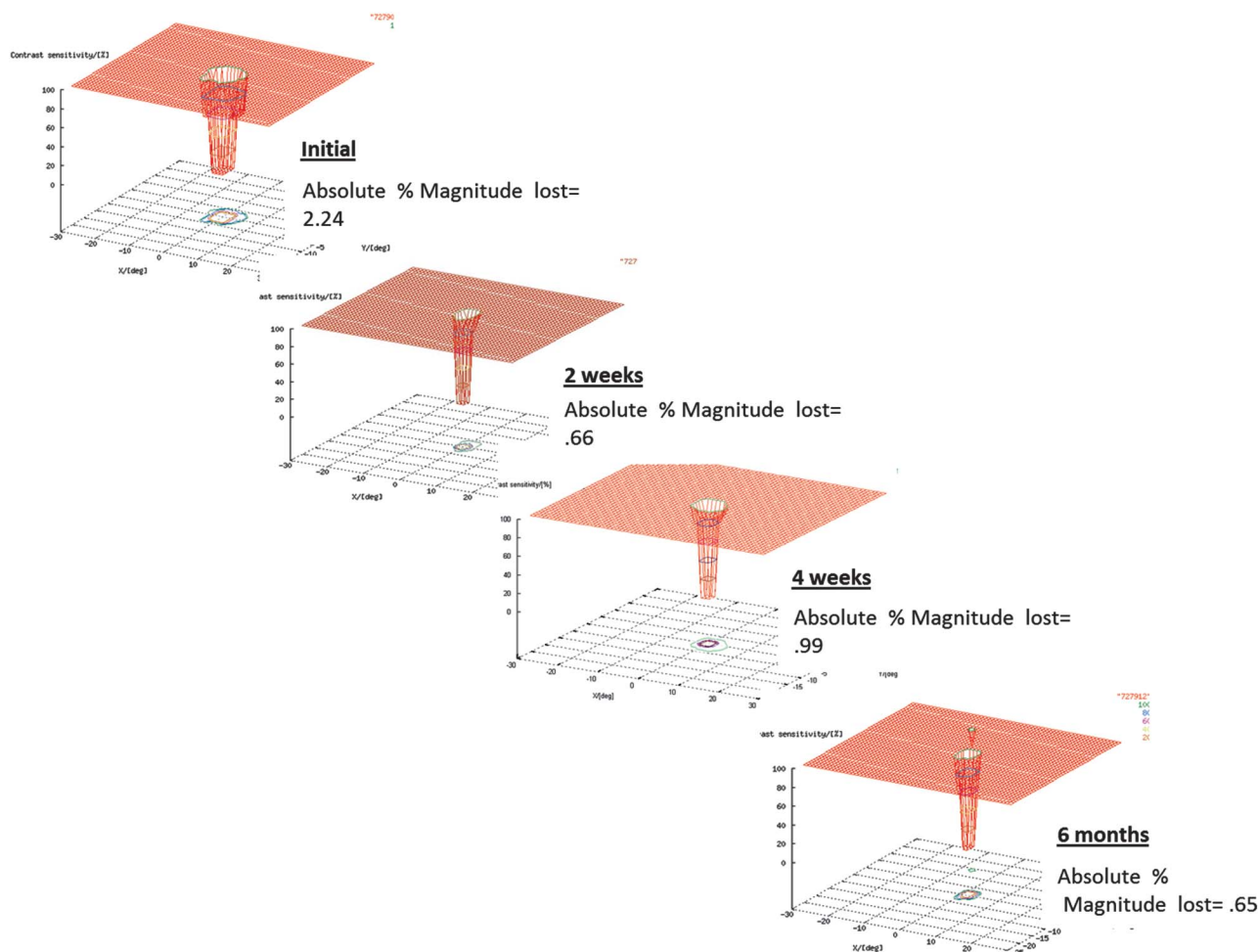


Fig. 2. Three-dimensional CTAG plots of central visual field function. Changes in macular function (i.e., Amsler grid and contrast sensitivity) are plotted over time by 3D-CTAG graphs. The top left corner shows the central visual abnormality at presentation, while the bottom right represents the abnormality at 6 months. In these graphical representations of the central visual defects, the x-axis and y-axis represent the area of visual field tested by Amsler grid, while the z-axis (vertical line to left in each plot) represents contrast sensitivity.

Table 1. Quantitative Functional and Structural Indices

	Visual Acuity	Absolute % Magnitude Lost	Macular Volume (μL)
Initial	20/200	2.24	0.32
2 weeks	20/40-2	0.66	0.22
4 weeks	20/40	0.99	0.21
6 months	20/50	0.65	0.21

after treatment, there were residual structural and functional deficits present 6 months after the injection (Table 1). The relative percent improvement in central macular volume over the first 2 weeks was 31% (0.32–0.22 μL), while the 3D-CTAG percent magnitude lost improved nearly 4-fold (from 2.24 to 0.66). Similarly, at 6 months, the central macular volume had improved slightly more to 0.21 μL (34% overall improvement), and the absolute percent magnitude lost showed a similar small improvement to 0.65 (400% overall).

Previous studies (Nazemi et al,² Kim et al,³ Nazemi et al,⁴ Robison et al,⁵ and Jivrajka et al⁶) have shown

that 3D-CTAG testing can differentiate various abnormalities based on specific patterns of visual dysfunction. For example, specific patterns were identified for wet versus dry AMD (Nazemi et al⁴ and Robison et al⁵), macular edema from diabetes as compared with AMD (Jivrajka et al⁶), and anterior ischemic optic neuropathy (AION) compared with optic neuritis (Fink and Sadun¹). Furthermore, 3D-CTAG has greater sensitivity in detecting wet AMD as compared with traditional Amsler grid testing (Robison et al⁵) and has also been shown to identify visual field defects earlier than Humphrey visual field testing in glaucoma suspect patients (Nazemi et al²). One testing modality to which

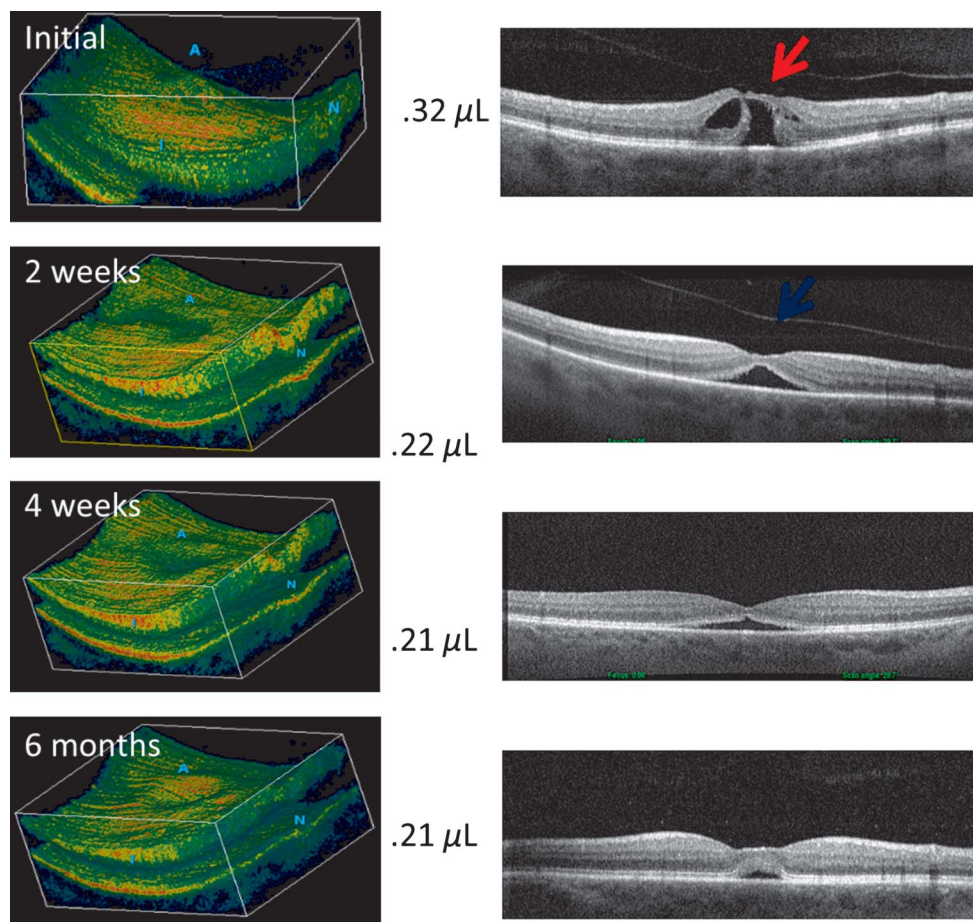


Fig. 3. Three-dimensional combined SD-OCT/SLO images. Three-dimensional color renderings and two-dimensional gray scale B-scans of combined SD-OCT/SLO imaging showing macular changes after pharmacologic vitreolysis with ocriplasmin. The initial scans shown on top demonstrates the elevated macula with VMA (red arrow) and extensive cystoid space formation. By 2 weeks, vitreous adhesions to the macula had resolved (blue arrow). The gradual restoration of the normal foveal depression and macular contours occurred over the ensuing 6 months.

3D-CTAG has not yet been directly compared is microperimetry. Microperimetry offers many of the same advantages as 3D-CTAG, such as a more detailed depiction of the visual function and high sensitivity of identifying visual defects. In addition, microperimetry adjusts for fixation error using retinal landmarks, making it more suitable for those with extensive central visual field loss. However, 3D-CTAG operates on much simpler and less-expensive machinery while still providing in-depth analysis of visual function. Additionally, because 3D-CTAG uses Amsler grids as opposed to discrete points of light like microperimetry, it is well suited to identify and quantitatively characterize metamorphopsia, which microperimetry cannot.

This case demonstrates that 3D-CTAG correlates well with structural changes in the macula. Combining 3D-CTAG functional testing with advanced structural analysis should further our understanding of the role(s) that structural abnormalities play in affecting visual function of patients across a wide range of posterior segment abnormalities. Current studies (Tozer et al¹²) are correlating structure and function in patients with macular pucker to quantify the level of statistical correlation between these two testing modalities. It is hoped that using 3D-CTAG to study the response to surgical and nonsurgical therapies will provide metrics for gauging the benefits of new therapies designed to restore visual function and not just structural integrity.

Key words: vitreous, pharmacologic vitreolysis, macular hole, combined OCT/SLO imaging, central vision, contrast-sensitive threshold Amsler grid.

References

1. Fink W, Sadun AA. Three-dimensional computer-automated threshold Amsler grid test. *J Biomed Opt* 2004;9:149–153.
2. Nazemi PP, Fink W, Sadun AA, et al. Early detection of glaucoma by means of a novel 3D computer-automated visual field test. *Br J Ophthalmol* 2007;91:1331–1336.
3. Kim JK, Fahimi A, Fink W, et al. Characterizing ethambutol-induced optic neuropathy with a 3D computer-automated threshold Amsler grid test. *Clin Experiment Ophthalmol* 2008;36:484–488.
4. Nazemi PP, Fink W, Lim JI, Sadun AA. Scotomas of age-related macular degeneration detected and characterized by means of a novel three-dimensional computer-automated visual field test. *Retina* 2005;25:446–453.
5. Robison CD, Jivrajka RV, Bababeygy SR, et al. Distinguishing wet from dry age-related macular degeneration using three-dimensional computer-automated threshold Amsler grid testing. *Br J Ophthalmol* 2011;95:1419–1423.
6. Jivrajka RV, Kim JK, Fink W, et al. Quantitative analysis of central visual field defects in macular edema using three-dimensional computer-automated threshold Amsler grid testing. *Graefes Arch Clin Exp Ophthalmol* 2009;247:165–170.
7. Bababeygy S, Sebag J. Chromodissection of the vitreoretinal interface. *Retin Physician* 2009;6:16–21.
8. Sebag J. Pharmacologic vitreolysis. *Retina* 1998;18:1–3.
9. Sebag J. Pharmacologic vitreolysis—premise and promise of the first decade. *Retina* 2009;29:871–874.
10. Stalmans P, Delaey C, de Smet MD, et al. Intravitreal injection of microplasmin for treatment of vitreomacular adhesion: results of a prospective, randomized, sham-controlled phase II trial (the MIVI-IIT trial). *Retina* 2010;30:1122.
11. El-Ashry M, Hegde V, James P, Pagliarini S. Analysis of macular thickness in British population using optical coherence tomography (OCT): an emphasis on interocular symmetry. *Curr Eye Res* 2008;33:693–699.
12. Tozer K, Yee K, Fink W, et al. Three Dimensional Computer-Automated Threshold Amsler Grid Testing Predicts IS/OS Junction Disruption in Macular Pucker. Orlando, FL: American Academy of Ophthalmology; 2012.